

Fournier Syndrome: Experience of Treatment with Calcium Alginate with Silver

A.C.D. Schunck de Oliveira*, I. Mendes,

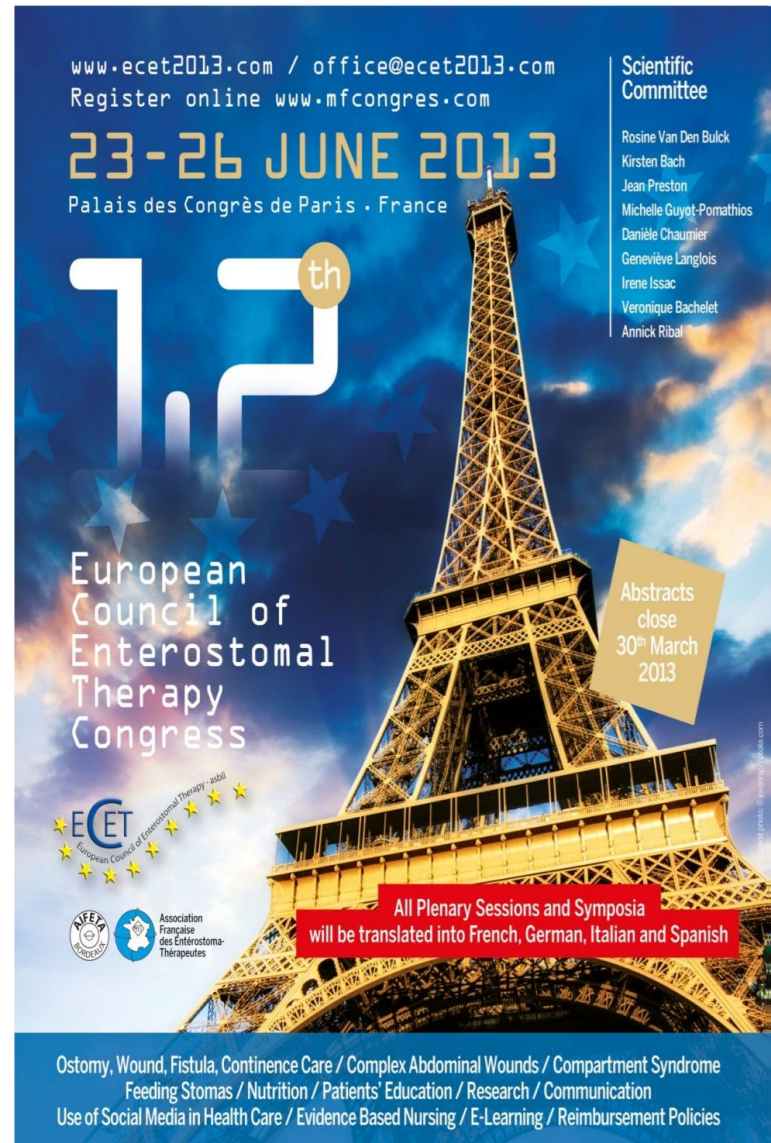G.D.Schunck de Oliveira, M.T. F. Costa, S. Scotá

Dr in Health Sciences

Stomatherapy Specialty

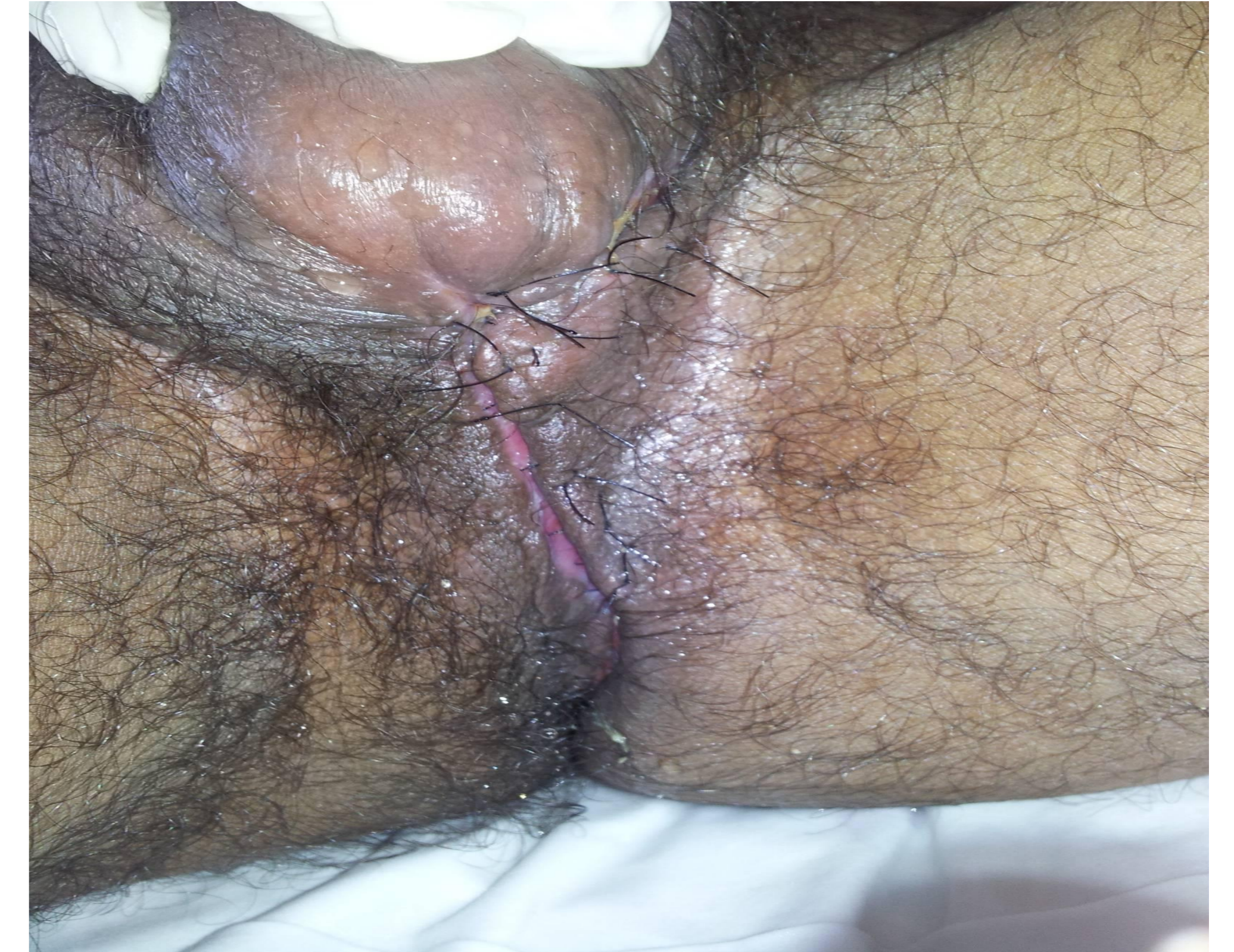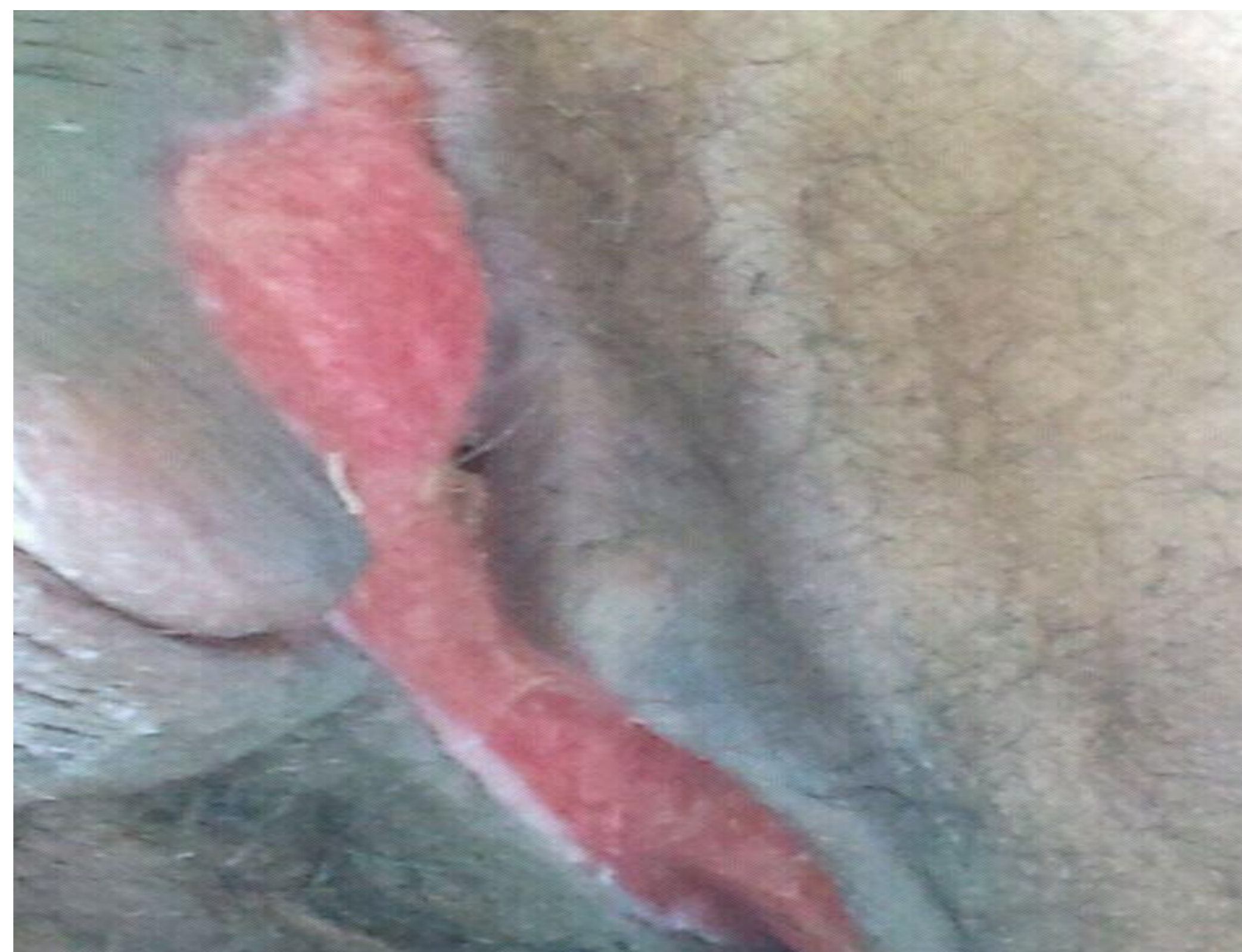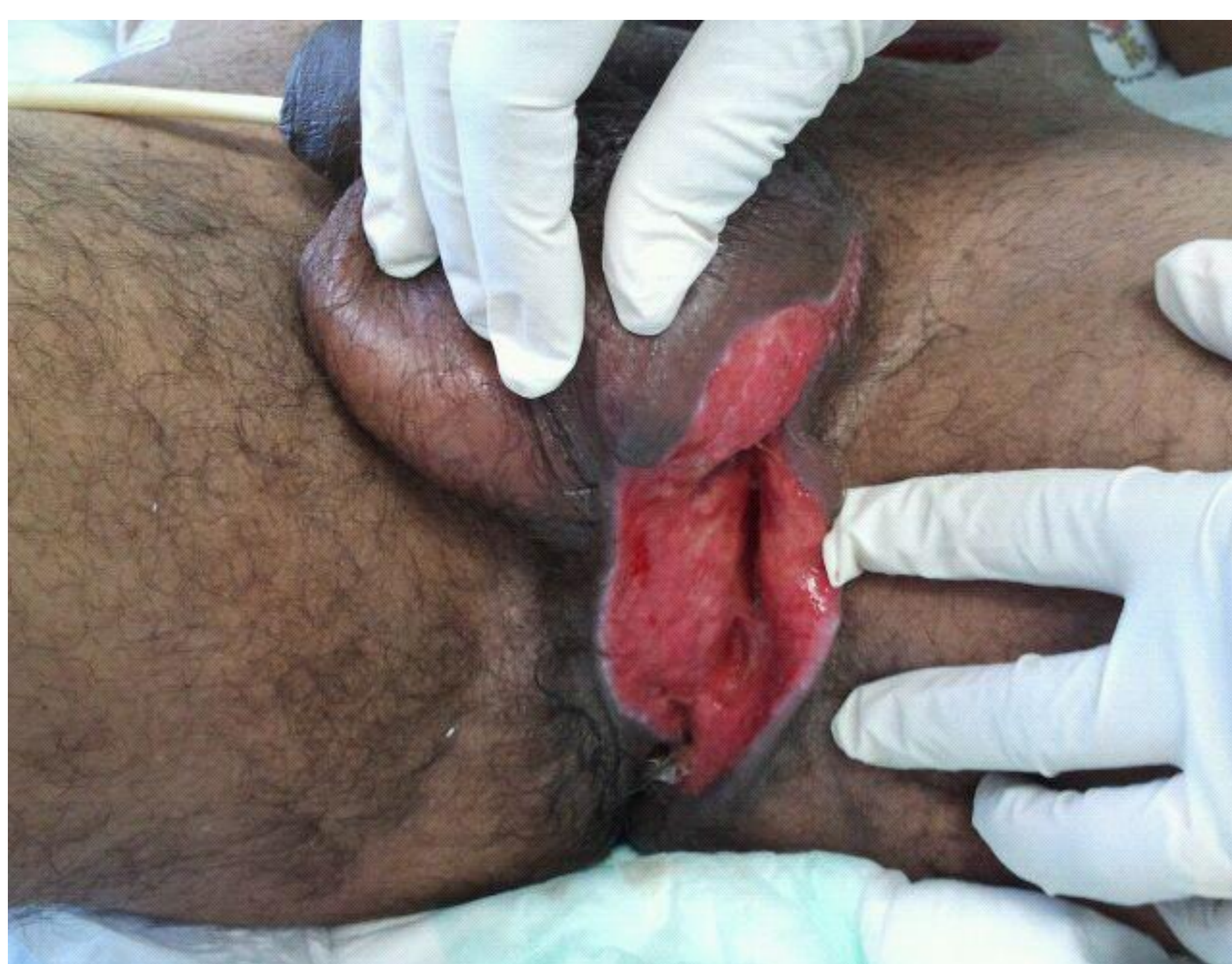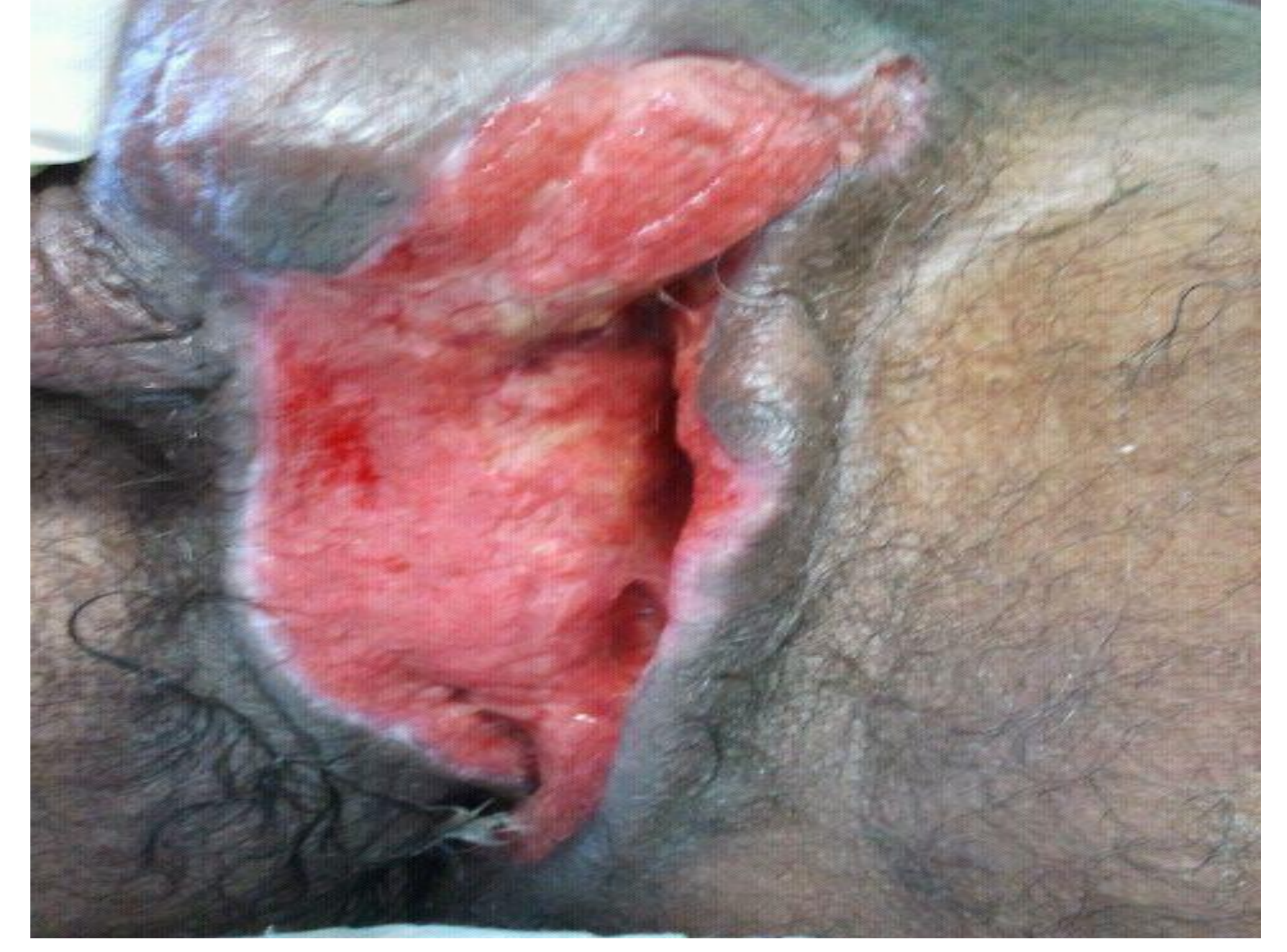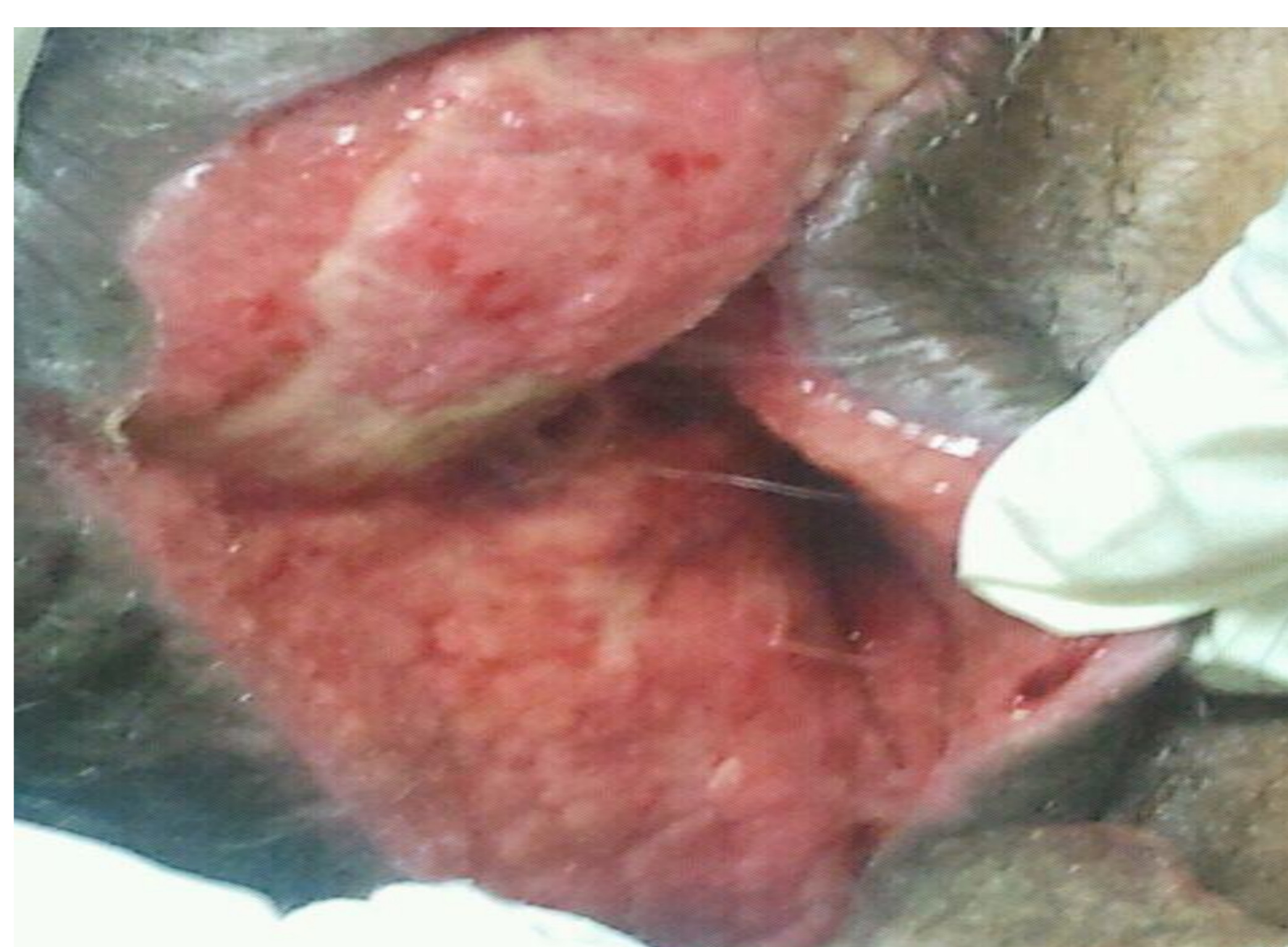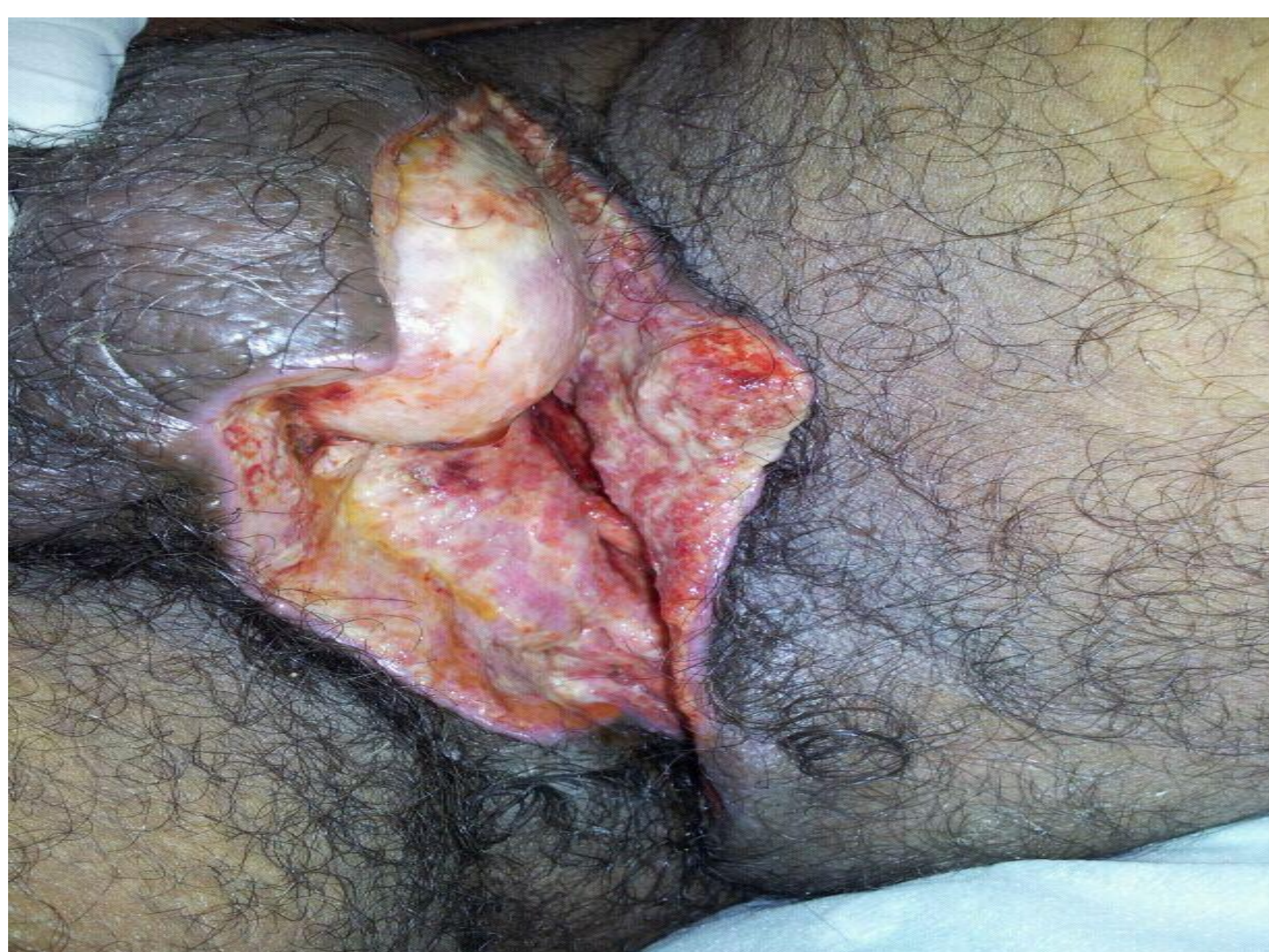
Instituto de Infectologia Emílio Ribas – São Paulo - Brazil

andreaschunck@hotmail.com*




Introduction: Fournier's syndrome, also known as necrotizing fasciitis syndrome Mellené or Fournier's gangrene is characterized by an acute infection of the soft tissues of the perineum with necrotizing cellulitis secondary to germs or anaerobic gram-negative bacilli, or both. **Objectives:** This study aims to report the experience of care topic of a syndrome of Furnier with calcium alginate with silver. **Methods:** This is a case study in the medicine ward of a public hospital of São Paulo. EAL, 49 years old, male, started with pain evolution with perianal seven days which started showing edema and hyperemia with poor general condition. 2012, april 14 day admitted with a diagnosis of ischial-rectal abscess. On April 23 conducted evaluation of the lesion, this showed total area: 45 cm², large amount of sero-sanguineous exudate, foul odor and complained of severe pain onsite, score 10. Performed with Calcium Alginate dressing with silver, changed every 24 hours.

Results: On the 8th day was revalued, with improvement of the appearance of the lesion, decreased pain (score 4), decreased tissue slough and necrosis and increased granulation tissue, no odor and small volume of serous exudate, maintaining the conduct. On the 13th day care showed significant decrease of the size of the wound, with total area of 18 cm². **Conclusion:** The care coverage adopted using calcium alginate with silver proved effective in healing injuries caused Fournier's syndrome, resulting in the successful evolution of the lesion, corroborating the patient in hospital on 30/05/12 with total closure of wound.



SUPPORT



References:

1. Laucks SS. Fournier's gangrene. Surg Clin North Am 1994; 74: 1339-52.
2. Figueredo LNPF et al. Fascíte necrotizante (Síndrome de Fournier) e revisão da literatura. Revista da Universidade de Alfenas. Alfenas. v.3, n.1, Supl. 1, p.11-17, ago.1997.
3. Yaghan RJ, Al-Jaberi TM, Bani-Hani I. Fournier's gangrene. Changing face of the disease. Dis Colon Rectum 2000; 1300-8.